

Predictable Tooth Replacement in the Aesthetic Zone



Joyce L.
Bassett, DDS

INTRODUCTION

Although perfection is never attainable, excellence is always expected. As dentists, we are faced with complicated situations involving both diagnostic and treatment complexities. We attempt to simplify our procedures so we do not overlook details that sacrifice predictability, longevity, or aesthetics.

At the Kois Center we are taught, “intellectualize simplification,” and we systemize protocols for all procedures. Through the American Academy of Cosmetic Dentistry (AACD), we are presented established accreditation examination criteria to evaluate the parameters for aesthetic excellence, giving us a checklist for optimal outcomes. The journey through the AACD examination process trains your eyes to see the nuances first, followed by the discerning implementation of manual skills.

Many dentists find implant placement, bone grafting, and socket preservation procedures exciting, challenging, and fun. I am not one of those dentists. I have taken a multitude of implant courses, watched and participated in implant surgeries (fixture placement and bone grafting), and nonetheless am

Many dentists find implant placement, bone grafting, and socket preservation procedures exciting.... I am not one of those dentists.

happy outsourcing the surgical aspects of this care. I believe in leveraging the skills and core competencies of my team that includes periodontists, endodontists, orthodontists, and oral and maxillofacial surgeons.

The team approach centers around the coordination of care with a comprehensive treatment plan understood by all parties, especially the patient. It is the teamwork and synergy among these individuals that allows the realization of the visualized treatment result.

Dealing with more complex cases involving defects in bone, compromised soft tissue, space management, and high smile-lines (aesthetic zone challenges) will test the



Figure 1. Patient presented with an Essex appliance with a denture tooth to replace tooth No. 10.

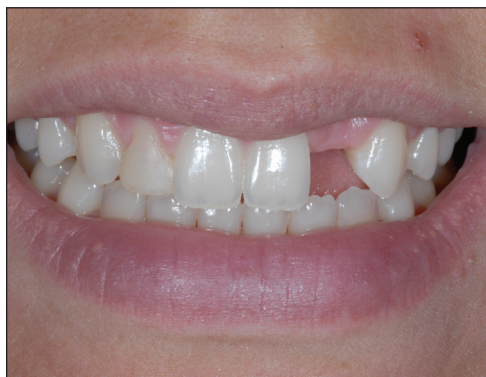

Figure 2. Pre-op smile. Tooth No. 7 was triangular shaped at gingiva with a high scallop and guarded Cupid's bow smile (high-risk assessment).

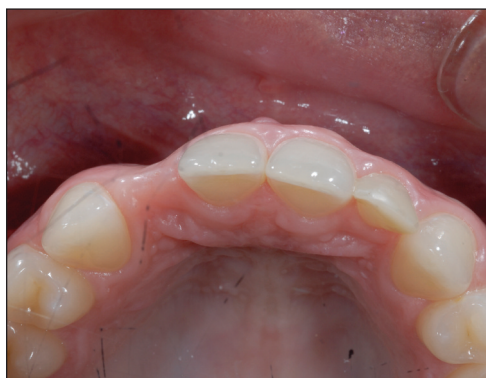

Figure 3. Incisal view. Note: tooth No. 10 showing a deficient/compromised ridge and inadequate soft-tissue topography.

team's ability to manage and deliver a natural appearing reconstruction. The ultimate aesthetic outcome requires ideal hard- and soft-tissue topography. The restoration must have natural anatomy and components of color. The patient's expectations must be understood and managed. Educating the patient about the risks and prognosis facilitates trust in the team and understanding of the proposed outcome. The restorative challenges must be identified and communicated to all team members.

Training, anticipation, planning, and communication are paramount. For the final restoration to meet the highest standard, it must be placed precisely both vertically and horizontally. The restorative dentist must understand minimum space requirements for implant placement. This often requires an orthodontic referral. Deficiencies in hard and soft tissue must be addressed and often require a surgical solution. Once these issues are addressed, proper placement of the implant is possible so the final restoration will have sufficient tissue and result in a natural form. Ideally, the emergence profile is designed to reflect the morphology of the contralateral natural tooth.

CASE REPORT

Diagnosis and Treatment Planning

A 17-year-old female patient (Figure 1) presented with an unsightly composite bonded to her right lateral incisor (tooth No. 7) and a congenitally missing left lateral incisor (tooth No. 10). Her initial goal was to attain a “natural, beautiful appearance.” Her main questions related to whether she was ready for implant placement.

She was referred from the orthodontist and presented wearing an Essex appliance with a plastic denture tooth to replace the missing tooth (No. 10). The edentulous site corresponding to tooth No. 10 was not ideal in terms of soft tissue or bone volume. The right central was disproportionately larger than the left central incisor, and asymmetry was visual at the free gingival margin. Her dental midline was concentric with her facial midline. On smiling she displayed a guarded Cupid's bow gingival smile-line, defined by the absence of display of the

continued on page 78

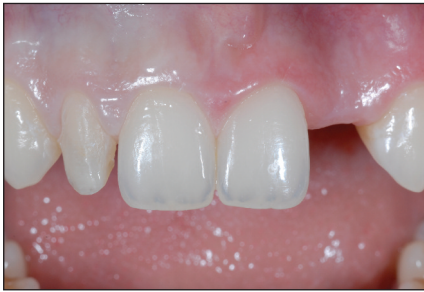

Figure 4. Right maxillary peg lateral under unsightly composite and asymmetrical centrals.

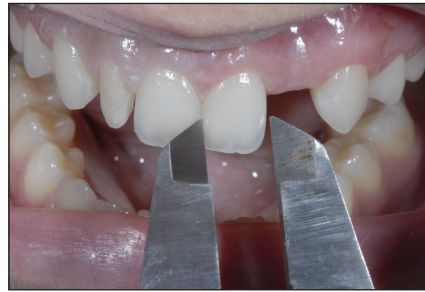

Figure 5. Measuring the mesiodistal width of teeth Nos. 8 and 9. Note: No. 9 is thinner.

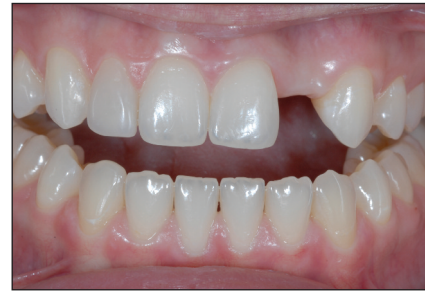

Figure 6. No. 7 composite veneer and space equalization finalized; harmonized and balanced aesthetically.

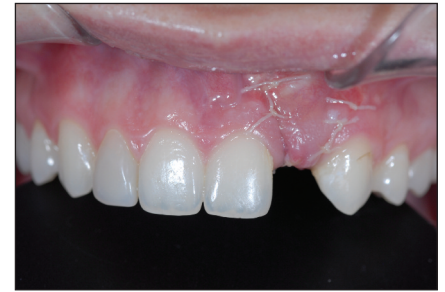

Figure 7. Post-op labial view, bone graft and implant placement completed.

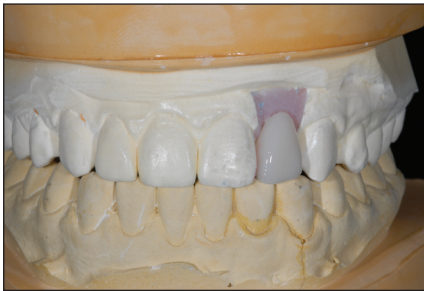

Figure 8. Lab-fabricated prototype. Note: tooth form is too square and apical in the gingival third compared to No. 7.

Predictable Tooth Replacement...

continued from page 76

midfacial gingival tissue of the central incisors (low smile-line) combined with the display of midfacial zenith gingival tissue on other maxillary teeth in the aesthetic zone (Figure 2).¹ This illustrated a high-risk assessment with a poor prognosis, since everything in the visual field (Nos. 7 and 10) needed to be restored. She presented with thin gingival tissue, and the gingival biotype, critical to a successful result, was in need of volumetric enhancement. She exhibited high gingival scallop, and the contralateral tooth, which would be mimicked in the final restoration, exhibited triangular tooth shape. The hard-tissue morphology was inadequate from a horizontal and labial perspective and in need of augmentation (Figure 3). The treatment goal would be to decrease the risk and increase the prognosis.²

The orthodontic workup included lateral cephalometric tracings (dated September 2007 and July 2009). These were evaluated and compared, and it was confirmed that no facial growth had occurred during the observed period. The patient also had symptomatic third molars that needed removal.

A surgical consult was recommended and scheduled after the restorative dentist solved the space management quandary. The patient's father was present for this consultation and was firm in his opposition to the placement of veneers on virgin teeth (Nos. 8 and 9). He requested a

DEVELOPING SUBGINGIVAL EMERGENCE PROFILE TO SUPPORT AND SHAPE THE SOFT TISSUE

Figure 9. Developing the outline form shape, height, and level of zenith to mirror the contralateral tooth.

Figure 10. Submergence profile on the facial is flattened and undercontoured subgingivally under the zenith area, allowing for movement in an incisal direction of the free gingival margin.

Figure 11. Lateral pressure was attained interproximally by recontouring the mesial and distal portion of the crown, offering support to the papilla.

minimally invasive solution. The patient's determination to preserve her natural smile established the parameters for planning the case.

Measuring the width of the contralateral incisors was the most logical first step. In all cases like this one, shape and form of the teeth must be assessed. Removal of the unattractive composite and replacement with a new imperceptible composite veneer that would duplicate the aesthetics of her existing teeth was recommended (Figure 4).

The remaining spaces would then be equalized, by performing additional direct bonding on the distal of the left central to achieve central incisor symmetry. After the entire direct composite has been placed and idealized, determination of additional tooth movement can be made. If minor tooth movement were necessary, it could be implemented, followed by implant placement. The patient agreed with this approach and was scheduled.

Space Management and Restorative Execution

Extrinsic stain was removed from all tooth surfaces using plain pumice on a soft prophyl cup. The unsightly composite on tooth No. 7 was removed and space evaluation was performed by measuring the space with a caliper (Figure 5). Shade selection occurred immediately to avoid any possibility of desiccation of the teeth that would lead to a mismatch after the tooth rehydrat-

ed. A small increment of composite was light cured, previewed, and then verified for color. The tooth was micro-etched (Micro Etcher II [Danville Materials]),³ rinsed, and a 37% phosphoric etch was agitated with a micro-brush for 15 seconds. The tooth was rinsed for 5 seconds and lightly air-dried. A fifth-generation adhesive (Scotchbond Universal [3M ESPE]) was applied and agitated for 20 seconds and air-dried for 5 seconds in order to remove the ethanol solvent. The area was then light cured for 10 seconds. This total-etch and adhesive technique was used on all surfaces of tooth to which composite was augmented.

Composite placement on the distal facial of No. 9 followed by recontouring until both centrals measured identically in the width of the teeth and from a frontal view appeared contralaterally symmetrical in outline form.

A direct composite veneer on No. 7 was bonded using a freehand technique, and a nanofilled composite (Filtek Supreme Ultra [3M ESPE]) was selected due to its strength, sculptability, and shade matching capabilities. A microfilled composite resin (Durafill [Heraeus Kulzer]) was selected as the thinnest final facial layer. The silica particles are .04 μm in size, the fillers being 35% of the weight. This microfill composite is translucent and provides excellent polishability and long-term color retention.

The depth of color and vitality necessary to mimic the adjacent tooth

was complex and required many shades of composite. Shade WE (3M ESPE) was placed as the lingual shelf, followed by dentin lobe formation with shade A1D (3M ESPE). Kolor + Plus Modifier (lavender shade) (Kerr) was painted in between the lobes to provide internal characterization, color saturation, and diffusion of light. When creating this layer, the central incisor was examined and the incisal effects were mimicked, but lessened. A thin layer of Filtek Supreme Ultra AT (3M ESPE) filled in the space between the lobes and created the incisal translucency effect.

Shade A1B (3M ESPE) was placed in a very thin increment on the body (middle) of the tooth, and then the final facial layer (Durafill VS B1 [Heraeus Kulzer]) was carried across the whole facial of the tooth, extending to the free gingival margin. This layer created the translucency of the enamel and an illusion of depth. This stratification technique modulated the shades and allowed depth of color to come through from within the restoration, yielding an undetectable, lifelike restoration. Finishing and polishing discs (Sof-Lex [3M ESPE]) were then used to refine primary anatomy, which consists of the facial profile, outline form, and the incisal embrasures. The anatomy of a lateral incisor tooth shape and form ranges from square to ovoid to triangular. In order to decrease the risk and increase the

continued on page 80

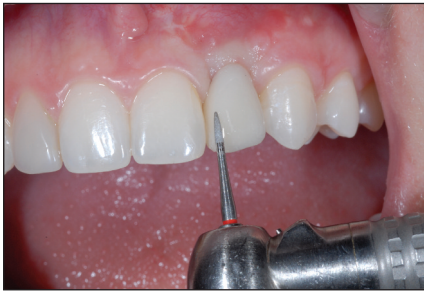

Figure 12. Flattening of the facial height of contour on the mesial facial outline form followed by adjusting the length and incisal embrasure. Note the contralateral symmetry.

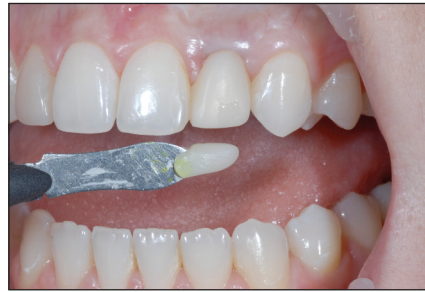

Figure 13. Custom shade tabs fabricated with composite resin (Venus Pearl [Heraeus Kulzer]). (The tab is placed in the same plane as the tooth being matched.)

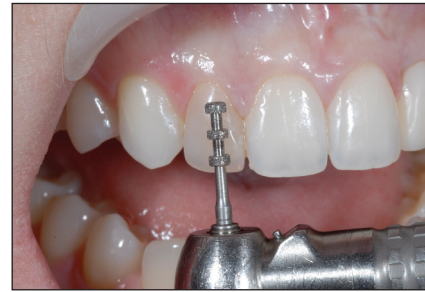

Figure 14. Depth-gauge cuts establish the amount of facial reduction.

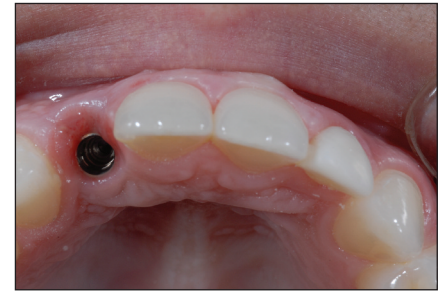


Figure 15. A concave transmucosal profile (occlusal view). Note the bilateral symmetry, augmentation of the osseous volume, and exact lingual positioning of the implant.

Predictable Tooth Replacement...

continued from page 78

prognosis, ovoid shape was chosen at the gingival third.^{2,4,5}

Secondary anatomy, which consists of line angles and reflective surfaces, was created using fine diamond burs (8889.31.009 [Brasseler USA]). A final luster was attained using spiral finishing wheels (3M ESPE), followed by placing a polishing paste on a felt wheel (Enamelize [Cosmedent]).

Measurements of the remaining space were accomplished, and verification of spacing equalization was attained (Figure 6). The patient was referred to the oral surgeon.

Surgical Treatment and Strategies

Successful implants must serve as a foundation for a naturally aesthetic prosthesis that provides both form and function as close to the natural dentition as is possible. Proper positioning of the implant, adequate stable bone volume and architecture and adequate soft-tissue thickness at the transmucosal connection (tissue biotype) are all significant factors affecting stability, health, and aesthetics. The ideal implant position is dictated by the balance between the desired final form and function of the prosthesis and the physiology and anatomy of the available hard and soft tissues. Because of the significant bone atrophy on the crestal and labial surfaces of the maxilla, a corticocancellous block onlay bone graft was performed on this patient.

The bone was harvested from the left external oblique ridge at the time her wisdom teeth were removed, 4 months prior to placement of the implant. The underside of the graft was shaped so that it sat passively in the crestal and labial defects. The contact with the underlying bone was intimate. It was secured with a single 10-mm x 1.7-mm titanium lag screw, placed in an incisal to apical angulation. This was done so that minimal soft-tissue dissection would be neces-

sary at the time of implant placement when the lag screw was removed.

Of significant importance at the time the graft is placed is the establishment of a passive, well-vascularized primary closure with a rigidly fixated bone graft. This is accomplished during the establishment of the labial flap. The adjacent papillas are preserved, and trapezoidal releasing incisions are made. A subperiosteal dissection is then completed. In a transverse direction, the periosteum is anatomically dissected from the overlying muscle, taking great care to preserve the vascular pedicle to the flap. It is then anatomically incised. With gentle blunt traction, the flap is then easily mobilized. This creates the volume needed to accommodate the underlying bone graft and permits eventual enhancement of the tissue biotype, while at the same time accomplishing a passive vascularized primary closure. The flap tends to swell for the first couple of days after surgery; consequently, the placement of the provisional prosthesis was delayed to avoid ischemia to the flap during the early postoperative period.

After 4 months of healing, a bone level 4.1 x 10-mm SLActive (Straumann) implant was placed. The rough osseointegrative surface and horizontal offset (Straumann's Bone Control Design) is felt to be a very effective design in maintaining bone against functional load. The crestal bone level is critical to the preservation of the mucosal barrier, and therefore to the long-term health and success of the implant/prosthetic unit. The depth of the implant placement is dictated by the facial height of the contour of the bone at the contralateral incisor. The patient's age should be taken into consideration, understanding that natural degrees of bone and tissue recession that may occur with time.

The flap was then developed, starting with the palatal aspect of the crestal incision. The incision was carried in a labial direction, preserving the papilla while making minimal

trapezoidal releases. This allowed for adequate exposure to identify and remove the lag screw, which was used to secure the bone graft.

A vacuum-formed surgical guide (fabricated by the restorative dentist) was employed to assure proper positioning of the implant. The implant was placed toward the palatal aspect of the maxillary alveolus at a 15° inclination. A healing abutment was then placed. The aspect of the flap that covered the crestal area of the graft was then de-epithelialized and rolled underneath the proximal aspect of the flap. This served as a vas-

Consistent evaluation of every step in the procedure is paramount to the success of the case.

cularized connective tissue graft and was done to enhance the labial contour of the cortical bone and to contribute to the perception of a root eminence. The wound was then closed anatomically (Figure 7).

Transitional Prosthesis

While grooming soft tissue is not essential to achieving gingival aesthetics, the technique utilized in this case simplifies the fabrication of the definitive porcelain while eliminating the guesswork on shape and form for the ceramist.⁶ The interproximal bone levels on adjacent teeth dictate the papillary height.⁷ Predicting the level of facial tissue can be accomplished 85% of the time by probing to the osseous crest of the adjacent tooth. The goal is to develop and guide the rebound of the soft tissue so as to mimic the root of the tooth and create scalloped forms identical to the contralateral area.⁸

The healing abutment was removed, the reverse torque test at 20 Ncm verified integration, and the impression coping was screwed into place. Radiographic confirmation of complete seating was accomplished.

A fixture level impression was done, a photo taken for the documentation of color, followed by fabrication of a laboratory fabricated provisional screw-retained composite crown (Symphony [3M ESPE]). *Consistent evaluation of every step in the procedure is paramount to the success of the case.* The case was returned from the ceramist and, on evaluation of the model (Figure 8), it was noted that the zenith and scallop of the composite prototype was more apical and wider at the apical third than the composite veneer on the right lateral. Immediate recontouring of the height of the

composite prosthesis was accomplished to mimic the contours of the contralateral tooth (Figure 9).

The healing abutment was removed, and the interproximal contacts were adjusted to ensure complete seating of the crown. This was then verified with a radiograph. Next, the submergence profile on the facial was flattened and undercountoured subgingivally (Figure 10). Lateral pressure was attained interproximally by recontouring the mesial and distal portion of the crown to offer support to the papilla (Figure 11). This facilitated proper molding of the tissue with the composite prototype by manipulation of concavity to form and guide the tissue. This created an abutment form that was scalloped at the gingiva, mimicking the level of the scallop of the contralateral tooth. Primary anatomy was evaluated from a frontal perspective and compared to the facial outline form of the right lateral incisor.

The facial height of contour was flattened on the mesial, length was adjusted, and incisal embrasure forms were checked (Figure 12); when the

continued on page 82

Predictable Tooth Replacement...

continued from page 80

outline form mimicked the contralateral tooth, the occlusion was checked. Verification of clearance from occlusal, protrusive, and cross overloading was achieved to control the early functional stress to the implant.

The patient was instructed to never allow food to be placed between this restoration and any opposing tooth.⁹ A 20 Ncm torque force was employed to secure the abutment screw in the access opening. It was then covered with cord and composite. The occlusion was then checked on all postoperative visits to verify that supereruption of the opposing dentition did not occur.

The precise anatomy should incorporate normal root contours and properly placed cemento-enamel junctions. These contours support the tissue at the proper levels mirroring the contralateral anatomy. Adjustment to the contours will affect the gingival shape and scallop form. On postoperative visits, composite can be added or subtracted to gain the desired result. The soft tissues adapt to the compressions of the composite prototype; if the composite is too full, this form will position the tissue apically. If the tissue at the zenith (the height of contour on the free gingival margin on the facial of the tooth) needs to be moved incisally, the composite prototype is flattened under the zenith.¹⁰ At-home bleaching trays were fabricated and 14% H₂O₂ bleach (Philips Zoom Day White) was dispensed. Monthly evaluation and recontouring occurred, and once symmetry was attained, the provisional restoration will function as a template for the porcelain.

Records

Color matching was accomplished by fabricating custom composite resin (Venus Pearl [Heraeus Kulzer]) tabs labeled with different colors and added to a wax spatula. The photographs were taken in the same plane

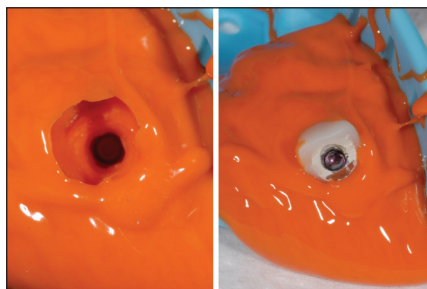


Figure 16. An impression of the provisional by seating it into the light body vinyl polysiloxane impression; used to fabricate a cast with the exact support papilla and free gingival margin height and contour.



Figure 17. The patient's goal was attained: a natural, beautiful appearance.

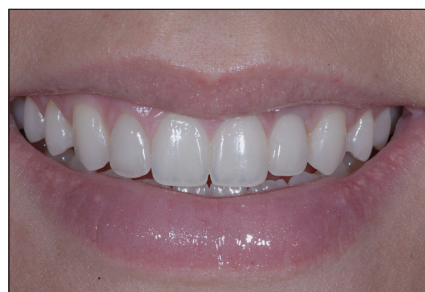

Figure 18. Post-op smile. Note the *big* Cupid's bow smile, normal root contours, papilla, and free gingival margin mirroring. This becomes "imperceptible dentistry."

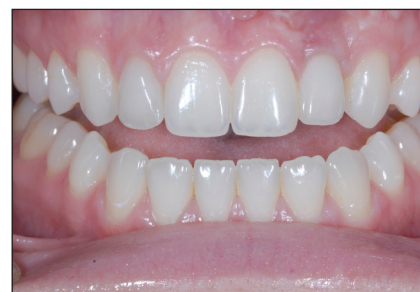

Figure 19. Post-op retracted view. Lifelike emergence profiles, tooth contours, and color.

as the facial surface of the tooth being used for comparison. These pieces were sent to the ceramist as part of the records needed for duplication of value and chroma (Figure 13).

Local anesthesia was administered, then a clear matrix vinyl polysiloxane (VPS) (Crystal [CLINICIAN'S CHOICE]) impression was taken of the maxillary quadrant from teeth Nos. 5 to 9. This record was used at the end of this visit to fabricate a new composite prototype to provisionalize the upper right lateral incisor. In order to establish the amount of facial reduction, depth gage cuts (828.31.030 [Brasseler USA]) were made across the upper middle and

lower middle third of tooth No. 7 (Figure 14). Next, 2.0 mm was removed from the previously approved incisal edge length, and then the veneer preparation was finalized.

The provisional screw-retained composite crown was then removed (Figure 15) and an impression coping was screwed into place, followed by radiographic verification of complete seating. The subgingival envelope must be reproduced so the ceramist can duplicate it in the final restoration. One technique is to duplicate this area using a customized impression coping. This coping is then taken to the mouth to support the soft tissue when taking the final impression. An alternative technique involves

fabricating an impression of the provisional by seating it into the light-body VPS impression (Figure 16). This allows a cast of the soft-tissue emergence profile, which communicates the exact support of soft tissue to replicate the papillary and free gingival margin height and contour.^{11,12}

A hemostatic, atraumatic, cord-free retraction putty (Expasyl [Kerr]) was placed intrasulcular on tooth No. 7 and then, as directed, rinsed with water. A fixture-level full-arch impression (Imprint 3 [3M ESPE]), face-bow (Panadent), opposing impressions, and bites were recorded.

The provisional screw-retained composite implant abutment was torqued 20 Ncm into place. A bis-acryl composite (shade B1 Luxatemp [DMG America]) was loaded into the provisional matrix; the No. 7 prototype was fabricated and the cementation technique employed used a combination of 2 cements. Next, spot etching, then bonding with expired veneer cement (RelyX [3M ESPE]) in the tooth center, TempBond Clear (Kerr) temporary resin cement (employed at the periphery of the restorations), was followed by light curing. Milled zirconia abutments provide better optical properties over cast gold or titanium, but proper facial thickness must be present. Upon evaluation, adequate bulk (2.0 mm) was verified, and since zirconia has proven tissue biocompatibility,¹³ a zirconia abutment with titanium inserts was chosen. Lithium disilicate (IPS e.max [Ivoclar Vivadent]) was selected as the veneering ceramic due to its aesthetic properties and high flexural strength (400 mPa).

This patient is young and, even though all known parameters for success had been fulfilled, a screw-retained design was selected due to the option of retrievability. Gingival recession is the most common complication of anterior tooth implants.² In the future, if minor corrections to the prosthesis would be required, the fix could easily be done. The patient's provisional was also archived in her records box.

Cementation

Anesthesia was administered, the composite prototypes were removed, and the No. 7 veneer was tried in and evaluated for marginal fit and aesthetics. It was then cemented using the total-etch technique, adhesive (OptiBond FL [Kerr]), and a light-cured veneer cement (RelyX Veneer [3M ESPE]). A 35-Ncm torque force was employed in a wet environment to secure the titanium abutment screw. Ten minutes later,

it was torqued again to 35 Ncm. The access opening was covered with cord and composite.¹⁴

The recare protocol has included bone and soft-tissue monitoring every 6 months at the patient's recare visits.

CLOSING COMMENTS

This AACD Accreditation Fellowship case demonstrates that even high-risk case types can result in an excellent outcome. Key principles including interdisciplinary treatment planning, meticulous attention to detail, and skillful execution, can be tedious and time consuming. However, these difficulties are overshadowed by the excellent results achieved and increased patient satisfaction.

A letter from the patient, along with a photo (Figure 17), was sent to the entire treatment team, stating the following:

We just wanted to send over a picture of Nicole with her final results. It has been a long journey that includes you and your team, but it was well worth it. Nicole loves her new smile and is always smiling from ear to ear. We are so grateful for all the work you did!

When the postoperative photos are displayed at the AACD scientific session Showcase of Excellence (Figures 18 and 19), the conference attendees (mostly dentists and some dental technicians) evaluate all the displayed cases with a very discerning eye. They focus on:

- What is right?
- What is wrong?
- What is perceptible? and
- What dentistry has been performed?

Yes, there is a shadow of a scar and, yes, there are slight differences in opacities between the veneer and the implant crown. In the end, we must remember that perfection may not be possible, but excellence is!◆

Acknowledgment

The concepts demonstrated were learned from the Kois Center and through many courses presented by the AACD. The author would like to thank Dr. Karel DeLeeuw of Mayo Clinic for his surgical expertise, Dr. Howard Henry for orthodontic alignment, and Rick Durkee and Brad Patrick for the laboratory work and support.

References

1. Hochman MN, Chu SJ, Tarnow DP. Maxillary anterior papilla display during smiling: a clinical study of the interdental smile line. *Int J Periodontics Restorative Dent.* 2012;32:375-383.
2. Kois JC. Predictable single tooth peri-implant aesthetics: five diagnostic keys. *Compend Contin Educ Dent.* 2001;22:199-206.
3. Onisor I, Bouillaguet S, Krejci I. Influence of dif-

ferent surface treatments on marginal adaptation in enamel and dentin. *J Adhes Dent.* 2007;9:297-303.

4. Bassett J. To plan or not to plan: that is the question! Aesthetically guided transitional bonding for space management quandaries. *Dent Today.* 2012;31:128-131.
5. Bassett J. Conservative restoration of a traumatically involved central incisor. *Compend Contin Educ Dent.* 2012;33:264-267.
6. Leziy SS, Miller BA. Aesthetics in implant therapy: a blueprint for success and change. *Ann R Australas Coll Dent Surg.* 2010;20:28-35.
7. Choquet V, Hermans M, Adriaenssens P, et al. Clinical and radiographic evaluation of the papilla level adjacent to single-tooth dental implants. A retrospective study in the maxillary anterior region. *J Periodontol.* 2001;72:1364-1371.
8. Wood RA, Mealey BL. Histologic comparison of healing after tooth extraction with ridge preservation using mineralized versus demineralized freeze-dried bone allograft. *J Periodontol.* 2012;83:329-336.
9. Block M, Finger I, Castellon P, et al. Single tooth immediate provisional restoration of dental implants: technique and early results. *J Oral Maxillofac Surg.* 2004;62:1131-1138.
10. Phillips K, Kois JC. Aesthetic peri-implant site development. The restorative connection. *Dent Clin North Am.* 1998;42:57-70.
11. Jemt T. Restoring the gingival contour by means of provisional resin crowns after single-implant treatment. *Int J Periodontics Restorative Dent.* 1999;19:20-29.
12. Neale D, Chee WW. Development of implant soft tissue emergence profile: a technique. *J Prosthet Dent.* 1994;71:364-368.
13. Linkevicius T, Apse P. Influence of abutment material on stability of peri-implant tissues: a systematic review. *Int J Oral Maxillofac Implants.* 2008;23:449-456.
14. Siamos G, Winkler S, Boberick KG. Relationship between implant preload and screw loosening on implant-supported prostheses. *J Oral Implantol.* 2002;28:67-73.

A graduate of The Ohio State University, **Dr. Bassett** practices comprehensive restorative and aesthetic dentistry in Scottsdale, Ariz. She is vice president and an Accredited Fellow of the American Academy of Cosmetic Dentistry. She is an associate member of the American Academy of Esthetic Dentistry, a Kois mentor, an active member in the Academy of Fixed Prosthodontics, and a Fellow in the AGD. Dr. Bassett is adjunct faculty where she teaches the aesthetic continuum at the Arizona School of

Dentistry. She is a national lecturer, published author, and is a member of the editorial board of several peer reviewed publications. She is also a Catapult speaker. Dr.

Bassett can be reached via e-mail at the address drmouthy@aol.com.

Disclosure: Dr. Bassett reports no disclosures.